37 Rosacea and Related Disorders

Síona Ní Raghallaigh

INTRODUCTION

The term "*rosacea*" encompasses a constellation of clinical findings, with either fixed centrofacial erythema in a characteristic pattern that may periodically intensify or phymatous changes classified as diagnostic features[1,2]. Other common features are papules and pustules, flushing, telangiectasia, and ocular manifestations such as blepharitis and chalazia. Many patients report increased facial skin sensitivity and dryness, often identifying specific aggravating triggers. The progression of rosacea is variable and at times unpredictable, with sporadic periods of exacerbations and remissions. For some patients, the psychosocial impact of this disorder can be marked.

HISTORY AND EPIDEMIOLOGY

Robert Willan is credited with the earliest medical descriptions of "acne rosacea" in the early 1800s, focusing on the papulopustular presentation. Nonetheless, estimating the true prevalence of rosacea has been limited over the years by discrepancies in disease definition, diagnostic methods, and study populations. Although some epidemiologic studies have reported a prevalence of 10% or higher in White adults[2], a systematic review of 32 studies examining 41 populations found a global adult prevalence of 5.5%[3]. In previous studies, women were observed to be affected by rosacea more often than men[4], but this systematic review found that rosacea affected both sexes equally. Notably, phymatous rosacea is rare in women.

Rosacea occurs primarily in adults older than 30 years of age, with the highest prevalence in individuals aged 45–60 years. While rosacea is rare in children, rosacea-like conditions such as periorificial dermatitis and steroid-induced rosacea are relatively common. Although described as a disease that predominantly affects individuals of Northern European descent with skin phototypes I and II[5], rosacea is likely underdiagnosed in individuals with darker skin phototypes in whom flushing, telangiectasia, and erythema are less perceptible[6].

Systemic comorbidities that may be associated with rosacea include inflammatory bowel disease, neurologic disorders (e.g. migraine, Alzheimer disease), and autoimmune diseases (e.g. multiple sclerosis, rheumatoid arthritis)[7]. A possible explanation is shared genetic, environmental, and/or pathophysiologic factors but further investigations are needed.

PATHOGENESIS

Several different but interrelated pathomechanisms have been proposed for rosacea (Fig. 37.1), with predominant pathways reflecting clinical features.

Genetic Factors

Rosacea is more common in individuals of Northern European descent and concordance in monozygotic twins has been demonstrated. A genome-wide association study identified two single-nucleotide polymorphisms and three HLA alleles associated with rosacea[8].

Dysregulated Cutaneous Immunity

Dysregulation of the cutaneous innate immune system can lead to abnormal inflammatory responses to environmental stimuli and commensal microorganisms. Triggering this innate immune system leads to the release of antimicrobial peptides such as cathelicidin (LL-37). After LL-37 propeptide is secreted by keratinocytes and other epithelial cells, it is cleaved into its active form by proteases (e.g. kallikrein-5). Active cathelicidin peptides then induce both proinflammatory and angiogenic activity. In the facial skin of individuals with rosacea, there are abnormally high levels of LL-37 (see Fig. 37.1)[9]. Also, LL-37 has been shown to contribute to inflammation via activation of the NLRP3 inflammasome (see Fig. 4.2)[10].

Toll-like receptors (TLRs) are pathogen-associated molecular pattern sensors that are involved in cutaneous innate immunity (see Fig. 4.1). In rosacea, keratinocytes express elevated levels of TLR2, leading to increased expression and activity of kallikrein proteases and thus cathelicidins[11]. In addition, matrix metalloproteinases, which activate kallikrein 5, are up-regulated in patients with rosacea[12]. Mast cells, which also release cathelicidin, are increased in number within the dermis of rosacea patients[13]. Lastly, in addition to dysregulated innate immunity, an abnormal adaptive immune response has been observed in rosacea, with Th1/Th17 polarized inflammation and macrophage infiltration[14].

Neurogenic Inflammation

Patients with rosacea often report sensations of stinging or burning of their skin, with affected individuals exhibiting lower heat pain thresholds when compared to controls[15]. When cutaneous nerve endings expressing transient receptor potential vanilloid (TRPV) cation channels are stimulated by trigger factors (e.g. spicy food, heat, alcohol), this can lead to dysesthesia, flushing, and erythema[16]. Heightened TRPV activity has been detected in the skin of rosacea patients and it leads to neurogenic inflammation, i.e. an inflammatory response induced by sensory nerves in which neuromediators are released at the site of inflammation. These neuromediators can result in vasodilation, extravasation of plasma proteins, and recruitment of inflammatory cells (see Fig. 37.1).

Vascular Alterations

Several clinical features of rosacea, including transient erythema, persistent centrofacial erythema, telangiectasias and flushing, point to the role the vascular system plays in its pathogenesis. An increase in blood flow within skin lesions of rosacea has been demonstrated[17], and patients with rosacea flush more readily in response to heat. Histopathologic studies of lesional skin found an elevated expression of vascular endothelial growth factor (VEGF), CD31, and the lymphatic endothelial marker podoplanin (D2-40), implying increased stimulation of vascular and lymphatic endothelial cells[18].

Ultraviolet Radiation (UVR)

Exposure to UVB can induce angiogenesis and increase secretion of angiogenic factors (e.g. VEGF) from keratinocytes[19]. UVR also induces production of reactive oxygen species, which upregulate matrix metalloproteinases that lead to vascular and dermal matrix damage[20]. Although clinically the erythema and telangiectasias of rosacea can resemble telangiectatic photoaging, a case–control observational study provided evidence that they are distinct entities[21], but as expected can overlap.

Epidermal Barrier Dysfunction

Several clinical features of rosacea imply skin barrier dysfunction. Rosacea patients often report facial dryness, and studies have confirmed a lowered threshold for skin irritancy[22]. In rosacea skin, there is increased transepidermal water loss, a marker of epidermal barrier dysfunction. It has been suggested that disruption or abnormalities of the stratum corneum allow penetration of sensory irritants[23]. In addition, patients with papulopustular rosacea have an abnormal skin surface fatty acid

Downloaded for Anonymous User (n/a) at Egyptian Knowledge Bank from ClinicalKey.com by Elsevier on March 10, 2024. For personal use only. No other uses without permission. Copyright ©2024. Elsevier Inc. All rights reserved.

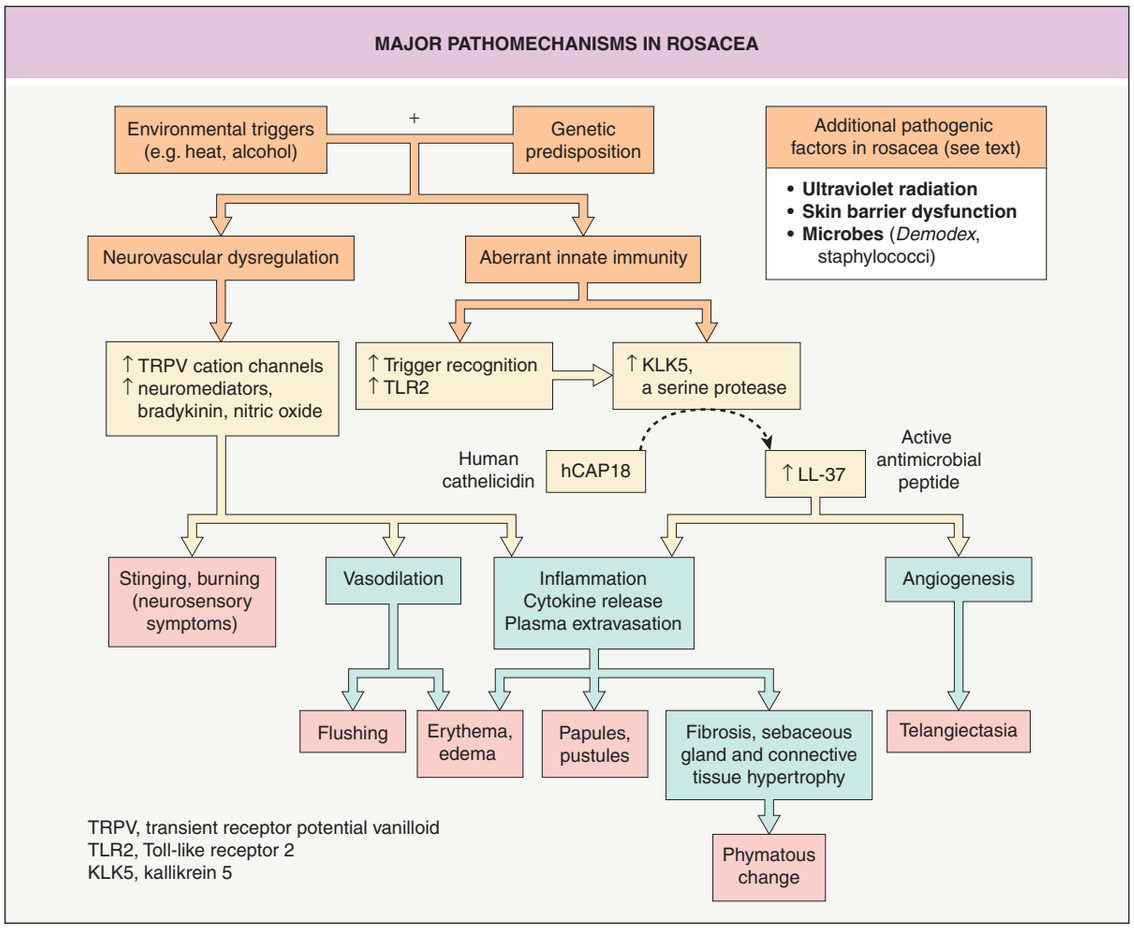

Fig. 37.1 Major pathomechanisms in rosacea. In genetically predisposed individuals (e.g. HLA-DRB1*03:01, HLA-DQA1*05:01, HLA-DQB1*02:01, SNP rs763035), environmental factors can trigger neurovascular dysregulation and an aberrant innate immune response, both of which can lead to cutaneous inflammation, including the clinical manifestations of rosacea. *Adapted from Steinhoff M, Buddenkotte J, Aubert J, et al. Clinical, cellular, and molecular aspects in the pathophysiology of rosacea. J Invest Dermatol Symp Proc. 2011;15:2–11.*

profile[24] as well as reduced epidermal hydration levels. The latter have been shown to improve following treatment with minocycline and resolution of inflammatory lesions[25].

Microorganisms

Demodex mites (*folliculorum* and *brevis*) are normally present on the face as commensal microbes, but in rosacea, greater numbers of these mites are detected by skin surface biopsy techniques[26,27]. In routine histologic sections, the mites often appear prominently within pilosebaceous follicles, and follicular infestation with multiple mites can be associated with an intense perifollicular infiltrate of predominantly CD4 T helper cells[28]. In addition, antigenic proteins from a bacterium (*Bacillus oleronius*) isolated from *Demodex* mites can stimulate inflammation in patients with papulopustular rosacea[29]. It has been suggested that *Demodex* mites and their associated bacteria upregulate local proteases, thereby potentiating dysregulation of the cutaneous innate immune response (see above)[30].

Study results differ as to whether *Helicobacter pylori* infection of the upper gastrointestinal tract plays a role in the pathogenesis of rosacea. A meta-analysis of 14 observational studies did not find statistically significant associations between either *H. pylori* infection and rosacea or *H. pylori* eradication therapy and symptomatic improvement of rosacea[31].

CLINICAL FEATURES

In 2002, a classification scheme divided rosacea into four main subtypes – erythematotelangiectatic, papulopustular, phymatous, and ocular – based upon the predominant lesion morphology[32]. However, it did not account for the frequent co-occurrence of more than one subtype nor the potential progression of one subtype to another. Recognizing these potential shortcomings, a revised classification of rosacea was recommended by the global ROSacea COnsensus (ROSCO) panel in 2016 and by the National Rosacea Society Expert Committee in 2017 (Table 37.1)[1,2].

PHENOTYPIC CLASSIFICATION OF ROSACEA (2017)
Diagnostic phenotypes
Fixed centrofacial erythema in a characteristic pattern that may periodically intensify
Phymatous changes
Major phenotypes
Papules and pustules
Flushing
Telangiectasia
Ocular manifestations*
Secondary signs and symptoms
Burning or stinging
Facial edema
Dry appearance of the skin
Ocular manifestations†

*Lid margin telangiectasia, interpalpebral conjunctival injection, spade-shaped infiltrates in the cornea, scleritis and sclerokeratitis.
†Honey-crust and collarette accumulation at the base of the lashes, irregularity of the lid margin, evaporative tear dysfunction (rapid tear breakup time).

Table 37.1 Phenotypic classification of rosacea (2017). A diagnosis of rosacea may be considered in the presence of at least one diagnostic or two major phenotypes. Secondary signs and symptoms may appear concomitantly with one or more diagnostic or major phenotypes. *Adapted from Tan J, Almeida LM, Bewley A, et al. Updating the diagnosis, classification and assessment of rosacea: recommendations from the global ROSacea COnsensus (ROSCO) panel. Br J Dermatol. 2017;176:431–8; and Gallo RL, Granstein RD, Kang S, et al. Standard classification and pathophysiology of rosacea: the 2017 update by the National Rosacea Society Expert Committee. J Am Acad Dermatol 2018;78:148–55.*

Downloaded for Anonymous User (n/a) at Egyptian Knowledge Bank from ClinicalKey.com by Elsevier on March 10, 2024. For personal use only. No other uses without permission. Copyright ©2024. Elsevier Inc. All rights reserved.

Both groups agreed that either one of the following two phenotypes are diagnostic of rosacea: (1) fixed centrofacial erythema in a characteristic pattern that may periodically intensify; and (2) phymatous changes. They also concluded that in the absence of one of these two *diagnostic phenotypes*, the presence of two or more of the following four *major phenotypes* can be diagnostic: (1) papules and pustules; (2) flushing; (3) telangiectasia; and (4) ocular manifestations. Secondary signs and symptoms that may also occur in conjunction with one or more diagnostic or major phenotypes include burning and stinging, facial edema, dry appearance of the skin, and other ocular manifestations.

Diagnostic Phenotypes (Table 37.2)

Fixed centrofacial erythema in a characteristic pattern that may periodically intensify

Persistent erythema of the central face is the most common presentation of rosacea in patients with skin phototypes I–III (Fig. 37.2). Of note, it may be more difficult to appreciate in darker skin phototypes. In addition, it can be challenging to differentiate from telangiectatic photoaging, although there are relative differences (see Table 37.4)[21]. In addition, other entities that can cause persistent facial erythema should be considered, e.g. lupus erythematosus, seborrheic dermatitis.

Fig. 37.2 Fixed facial erythema due to rosacea. There was greater involvement of the medial cheek. *Courtesy Frank C. Powell, MD.*

CLINICAL FEATURES AND MANAGEMENT OF ROSACEA				
Predominant phenotype	**Predominant clinical features**	**Severity**		**Management**
		Grade	**Features**	
Erythema and telangiectasia (formerly termed erythematotelangiectatic)	• Persistent centrofacial erythema • Flushing • Telangiectasia • Skin sensitivity	1	Occasional mild flushing; faint persistent centrofacial erythema; few telangiectasias	• General recommendations for facial skin care (see Table 37.5) • Reduce flushing • Minimize irritation • Topical treatments used in papulopustular rosacea may cause irritation • Laser therapy of prominent blood vessels in grades 2 and 3 disease
		2	Frequent troublesome flushing; moderate persistent centrofacial erythema; several distinct telangiectasias	
		3	Frequent severe flushing; pronounced persistent centrofacial erythema; many prominent telangiectasias; possible edema	
Papules and pustules (previously termed papulopustular)	• Persistent centrofacial erythema • Papules • Pustules/papulopustules • Overlap with other subtypes may occur	1	Few papules and/or papulopustules; mild persistent centrofacial erythema	• Topical or systemic medications for grades 1 and 2 disease • Systemic medications for grade 3 • May require repeated courses or gradual taper
		2	Several papules and/or papulopustules; moderate persistent centrofacial erythema	
		3	Extensive papules and/or papulopustules; pronounced persistent centrofacial erythema; inflammatory plaques or edema may be present	
Phymatous	• Thickened, nodular skin • Prominent pores • Can affect nose (rhinophyma), chin (gnathophyma), forehead (metophyma), ears (otophyma), eyelids (blepharophyma) • May be associated with other features of rosacea or occur in isolation	1	Puffiness; mildly patulous follicles; no clinically apparent hypertrophy of connective tissue or sebaceous glands; no change in contour	• Surgical or laser therapy for grades 2 and 3 rhinophyma • Other phymas are more difficult to treat but may improve with systemic treatments, if an inflammatory component is present
		2	Moderate swelling; moderately dilated patulous follicles; clinically, mild hypertrophy of the sebaceous glands or connective tissue; change in nasal contour without nodular component	
		3	Marked swelling; large dilated follicles; distortion of contour due to hypertrophy of the sebaceous glands and/or connective tissue, with a nodular component	
Ocular	• Dry, gritty sensation • Blepharitis • Conjunctivitis • Chalazia and hordeola • Keratitis, episcleritis, scleritis, iritis (rare)	1	Mild itch, dryness, or grittiness; fine scaling of eyelid margins; telangiectasia of eyelid margins; mild conjunctival injection	• Topical medications for grade 1 • Systemic medications for grade 2 • Refer to ophthalmologist for persistent grade 1 or 2 disease or suspected grade 3 disease
		2	Burning or stinging; crusting, irregularity, erythema and/or edema of eyelid margins; definite conjunctival injection; chalazion or hordeolum	
		3	Pain, photosensitivity, blurred vision; severe eyelid changes with loss of lashes, severe conjunctival inflammation; corneal changes, with potential loss of vision; episcleritis, scleritis; iritis	

Table 37.2 Clinical features and management of rosacea. *Adapted from Pelle MT, Crawford GH, James WD. Rosacea: II. Therapy. J Am Acad Dermatol 2004;51:499–512.*

Downloaded for Anonymous User (n/a) at Egyptian Knowledge Bank from ClinicalKey.com by Elsevier on March 10, 2024. For personal use only. No other uses without permission. Copyright ©2024. Elsevier Inc. All rights reserved.

Fig. 37.3 Rhinophyma. Hypertrophy of sebaceous glands and connective tissue as well as patulous follicles are seen. The changes are more prominent in the mid to lower nose. In addition, there is evidence of papulopustular rosacea. *Courtesy Kalman Watsky, MD.*

Fig. 37.4 Tortuous, telangiectatic vessels on the distal aspect of the nose contribute to its hyperemic appearance. This hyperemia may predispose to the subsequent hypertrophic changes of rhinophyma. Note the early sign of patulous follicles ("dilated pores"). *Courtesy Frank C. Powell, MD.*

TYPES OF PHYMATOUS ROSACEA	
Phyma	**Clinical features**
Rhinophyma	• Apparent initially as dilated patulous follicles at the distal end of the nose • When marked, can lead to debilitating nasal deformity
Gnathophyma	• Rare occurrence, with central chin typically involved • May give rise to asymmetrical swelling
Otophyma	• Usually affects the lower half of the helices and lobes of the ears
Metophyma	• Cushion-like, firm swelling of central forehead
Blepharophyma	• Swelling of the eyelids • Usually seen as a component of edematous rosacea but may accompany severe papulopustular or ocular rosacea

Table 37.3 Types of phymatous rosacea.

Fig. 37.5 Moderate papulopustular rosacea of the forehead. Note the superficial nature of the inflammatory lesions. *Courtesy Frank C. Powell, MD.*

Phymatous changes

These changes include sebaceous gland hypertrophy, patulous follicles, a bulbous appearance on the distal portion of the nose, and eventual fibrosis. Rhinophyma is by far the most common clinical presentation, occurring primarily in men (Fig. 37.3). Involvement of other anatomic sites has been reported, but it is rare (Table 37.3). Patients with rhinophyma may have other features of rosacea, usually mild to moderately severe papules and pustules. However, phymatous changes may arise *de novo* without any preceding skin changes and therefore should not be viewed as "end-stage rosacea"[33].

The earliest clinical sign of rhinophyma is the appearance of patulous follicles on the distal portions of the nose. It has been suggested that telangiectatic vessels in this same location may predispose to hypertrophic changes (Fig. 37.4). In severe cases of rhinophyma, the tissue hypertrophy leads to nasal distortion, with soft fleshy nodular growths resulting in significant disfigurement. Although basal cell carcinomas have been reported to arise in skin affected by rhinophyma, there is insufficient evidence to suggest that this condition predisposes to malignant change.

Major Phenotypes

Papules and pustules

Patients typically have a centrofacial eruption of multiple small (<3 mm), dome-shaped, erythematous papules and/or pustules that appear singly or in crops (Fig. 37.5 & 37.6). Individual lesions last about two weeks and are then replaced by blotchy postinflammatory erythema which gradually fades. Residual scarring is not a feature of papulopustular rosacea. A halo of erythema may surround larger inflammatory lesions and tiny telangiectatic vessels may be visible within this rim. Occasionally, when there is more severe disease, scaling or superficial crusting may be seen and this has been referred to as rosacea dermatitis (Fig. 37.7). Lastly, some patients will have some degree of persistent erythema of the cheeks that may represent a combination of postinflammatory erythema, telangiectasias, and vasodilation.

Flushing

Frequent flushing and blushing are common in patients with rosacea and occur in response to neurostimulation by various triggers (e.g. heat, alcohol consumption, certain social situations). Although quite noticeable in skin phototypes I–IV, flushing may be less visible in darker phototypes but rather experienced as a sensation of increasing warmth in the face. In addition, when patients complain of significant flushing, other causes of flushing should be considered as outlined in Tables 106.2 & 106.3.

Telangiectasia

Telangiectasias are common and involve primarily the central face, including the chin, in patients with lighter skin phototypes. They need to be distinguished from telangiectatic photoaging (see Table 37.4) and are less common as well as less perceptible in individuals with darker skin phototypes.

Downloaded for Anonymous User (n/a) at Egyptian Knowledge Bank from ClinicalKey.com by Elsevier on March 10, 2024. For personal use only. No other uses without permission. Copyright ©2024. Elsevier Inc. All rights reserved.

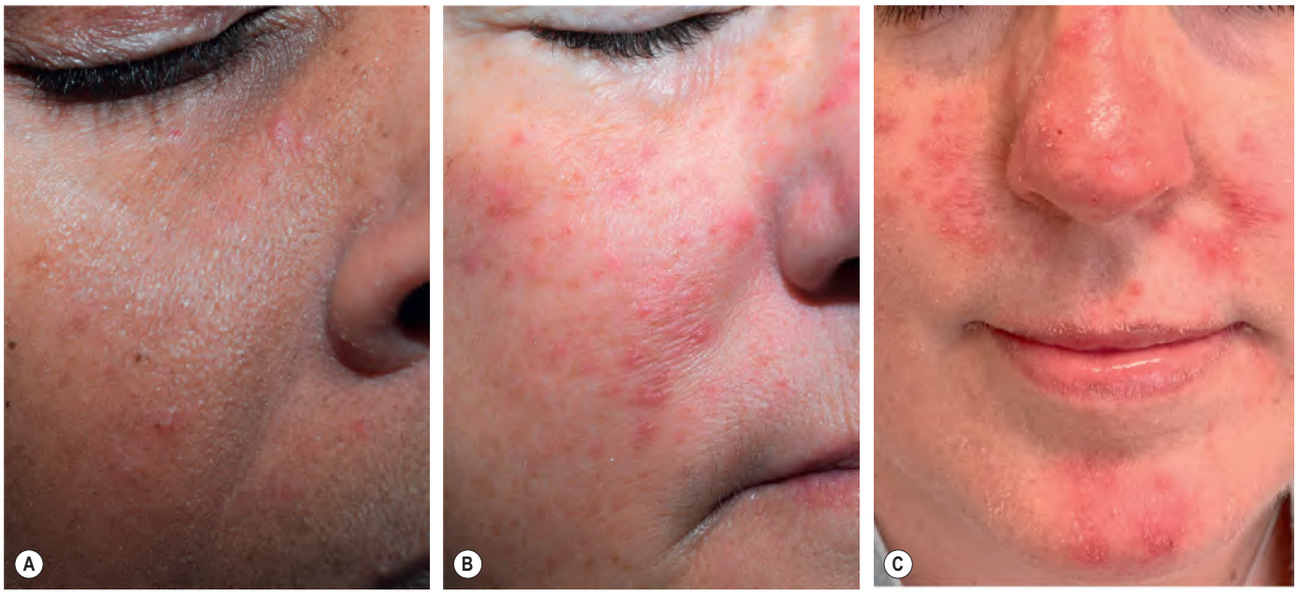

Fig. 37.6 Papulopustular rosacea – spectrum of severity in different skin phototypes. A Mild disease with scattered lesions on the cheek. **B** Moderate disease with increased number of lesions and areas of background erythema. **C** Severe disease with characteristic centrofacial distribution. Note the associated xerotic scale. *A, B, Courtesy Kalman Watsky, MD.*

Fig. 37.7 Rosacea dermatitis. When there is more severe disease, scaling and superficial crusting may be seen as on the cheek of this woman. *Courtesy Kalman Watsky, MD.*

Fig. 37.8 Inflammatory rosacea with edematous changes. An intensely erythematous plaque is present on the medial aspect of the cheek. This may improve once the underlying inflammation is treated appropriately. *Courtesy Frank C. Powell, MD.*

Ocular manifestations

Ocular manifestations of rosacea are discussed below.

Secondary Signs and Symptoms

Burning and stinging

Burning and stinging of the facial skin is a common complaint in patients with rosacea while pruritus is unusual. These sensations often occur within a background of erythema and sometimes scale. Patients also report significant sensitivity to and irritation from many products that are applied to the skin.

Facial edema

Facial edema may occur along with or result from prolonged erythema or flushing of the face and is thought to develop from post-capillary extravasation due to inflammation[2]. The soft edematous changes that are sometimes seen in patients with severe inflammatory rosacea (Fig. 37.8) should not be confused with phymatous rosacea. Such changes, unlike those of phymatous rosacea, often improve following successful management of the inflammatory lesions. Solid facial edema is discussed below.

Dry appearance

The centrofacial skin may sometimes appear dry and scaly, almost resembling a type of eczematous dermatitis. Such a presentation is often accompanied by burning and stinging sensations as well as significant sensitivity to topical products. When present, consideration should be given to the concomitant diagnosis of seborrheic dermatitis, which often coexists (see Table 37.4).

Other ocular manifestations

Ocular manifestations of rosacea are discussed below.

Other Clinical Rosacea Presentations

Ocular rosacea

This entity may or may not be accompanied by cutaneous changes of rosacea. Without cutaneous manifestations, the diagnosis of ocular

Downloaded for Anonymous User (n/a) at Egyptian Knowledge Bank from ClinicalKey.com by Elsevier on March 10, 2024. For personal use only. No other uses without permission. Copyright ©2024. Elsevier Inc. All rights reserved.

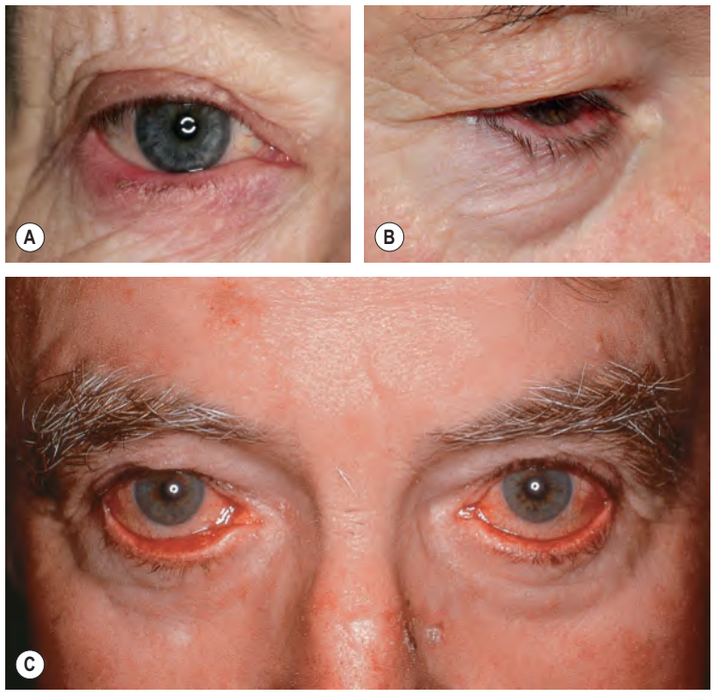

Fig. 37.9 Ocular rosacea. A Tiny concretions of keratin (conical dandruff) are visible at the bases of some of the eyelashes of the lower eyelid. There is also evidence of blepharitis of the lower eyelid and conjunctival injection. **B** Erythema of the mucosal portion of the lower eyelid and ectropion. **C** Marked injection of the conjunctivae, leading to the appearance of red eyes. Ectropion is also present. *A, Courtesy Frank C. Powell, MD.*

rosacea can be difficult to establish with certainty (Fig. 37.9). Symptoms are often nonspecific and include dryness, a gritty sensation, an inability to wear contact lenses, tearing, and sometimes pruritus. Patients usually do not associate these ocular symptoms with their rosacea and may not volunteer such information unless specifically asked.

Signs that strongly suggest a diagnosis of ocular rosacea include eyelid margin telangiectasias, interpalpebral conjunctival injection, and on slit lamp examination, corneal spade-shaped infiltrates, scleritis, and sclerokeratitis (see Table 37.1)[2]. Other common, but less specific, signs include honey crusting and mild scaling of the eyelid margin, tiny concretions at the bases of the lashes (conical dandruff; see Fig. 37.9A), and irregularity of the eyelid margin. When the disease is more active, there is evidence of blepharitis, often with eyelid swelling and conjunctival injection (see Fig. 37.9C). Cysts arising from the meibomian glands (chalazia) present as firm non-tender swellings of the cutaneous tarsal surface, while hordeola (styes) are often painful. Severe ocular disease (e.g. keratitis, corneal neovascularization, uveitis, scleritis, iritis) is rarely seen in patients with rosacea.

Granulomatous rosacea

In *granulomatous rosacea*, there are monomorphic, persistent, skin-colored to dull red–brown facial papules that are dome-shaped, favor the central face, and usually measure 1–3 mm in diameter (Fig. 37.10). This variant occurs in both children and adults and it may resolve spontaneously a few years after lesions first appear and not recur. Extrafacial lesions (e.g. on the scalp, neck, and upper trunk) are seen more often with the granulomatous variant. Histologically, non-caseating epithelioid granulomas are present within the dermis (see Pathology).

Some authors consider *lupus miliaris disseminatus faciei* (LMDF) to be a severe form of granulomatous rosacea[34], with a predilection for the periocular region (as well as the central face) and an "apple-jelly" appearance on diascopy. However, the dermal granulomas seen in biopsy specimens often have central caseation necrosis, thus explaining why this disorder was initially considered a tuberculid. More recently, *facial idiopathic granulomas with regressive evolution* (FIGURE) was proposed as an alternative term for LMDF. Unfortunately, significant facial scarring can be a permanent sequela. Occasionally, there is extrafacial involvement, which may be confused with other granulomatous

Fig. 37.10 Granulomatous rosacea, lupus miliaris disseminatus faciei variant. Monomorphous, discrete skin-colored to brown papules scattered on the face that are more persistent than the lesions of papulopustular rosacea. Histologically, granulomas with central caseation necrosis were observed, which led to the diagnosis of lupus miliaris disseminatus faciei.

diseases such as sarcoidosis, cutaneous tuberculosis, or the necrobiotic form of granuloma annulare.

Some authors consider both *rosacea conglobata*, which is characterized by an eruption of inflammatory cystic lesions that heal with scarring, and *rosacea fulminans* (pyoderma faciale) to be within the rosacea spectrum. In rosacea fulminans, an explosive onset of inflammatory papules and pustules is superimposed on a background of facial erythema, usually occurring in young women and sometimes during pregnancy[35].

DIFFERENTIAL DIAGNOSIS

The differential diagnosis for each of the diagnostic and major phenotypic subtypes of rosacea are outlined in Table 37.4.

PATHOLOGY

Histopathologic changes in erythematous and telangiectatic rosacea may be subtle and are often limited to vascular ectasia and mild edema (Fig. 37.11A). In the inflammatory papules and pustules, a more prominent perivascular and perifollicular lymphohistiocytic infiltrate appears (Fig. 37.11B). Sebaceous hyperplasia may be prominent in some patients. Comedo formation is notably lacking. In the granulomatous form of rosacea, non-caseating epithelioid granulomas are seen within the dermis (Fig. 37.11C). Phymatous rosacea shows dilated hair follicles, marked hyperplasia of sebaceous glands, and a variably dense lymphohistiocytic inflammatory infiltrate.

TREATMENT

General skin care recommendations for all rosacea patients are outlined in Table 37.5 and they represent an important component of the overall therapeutic regimen[36,37]. Currently available treatment options for the various subtypes of rosacea are listed in Table 37.6[38,39]. Grading the predominant features of rosacea into mild, moderate, and severe (grades 1–3) assists in guiding initial therapeutic interventions and in monitoring the clinical response (see Table 37.2)[40]. At the initial consultation, the patient should be made aware of the chronic relapsing nature of rosacea and the need for maintenance therapy even when in remission[5].

Transient and Persistent Erythema and Telangiectasia

A skin care regimen aimed at reducing skin sensitivity and improving epidermal barrier function is particularly important in these patients (see Table 37.5). In addition, strict photoprotection is advised, as UV exposure may potentiate dermal matrix and vascular damage. Topical application of vasoconstrictive adrenergic agonists, such as brimonidine (selective α_2) or oxymetazoline (selective α_{1A} and partial α_2), may help to diminish persistent erythema[41,42]. Patients should be instructed on the proper application of these agents and informed of side effects including rebound erythema, a burning sensation, and irritant contact dermatitis.

Topical antibiotics such as metronidazole may reduce erythema in a select group of patients, but they can cause irritation (see Table 37.6).

Downloaded for Anonymous User (n/a) at Egyptian Knowledge Bank from ClinicalKey.com by Elsevier on March 10, 2024. For personal use only. No other uses without permission. Copyright ©2024. Elsevier Inc. All rights reserved.

DIFFERENTIAL DIAGNOSIS OF ROSACEA	
Rosacea phenotype and differential diagnosis	**Distinguishing feature(s) from rosacea**
Erythema and telangiectasia (previously termed erythematotelangiectatic)	
Actinic damage (telangiectatic photoaging)	• Also characterized by facial telangiectasias and erythema, but the latter favors the lateral more than the central face • There tends to be less transient and non-transient erythema • Some patients have both disorders
Seborrheic dermatitis	• Erythema with greasy scale in the eyebrows, nasolabial folds, auditory meatus, retroauricular sulcus, and scalp • Involvement of eyelid creases • Patients often have both disorders
Keratosis pilaris rubra	• Onset usually during adolescence • Background erythema of the lateral cheeks with superimposed tiny follicular papules
Acute cutaneous lupus erythematosus	• Absence of inflammatory papulopustules and ocular changes • At least 75%–80% of patients have systemic signs/symptoms of SLE • Often more well-demarcated edematous plaques with sparing of the nasolabial fold
Dermatomyositis	• Violaceous erythema that favors the eyelids and central face, including the nasolabial folds • Eyelid edema can be pronounced
Flushing (idiopathic or secondary)	• Intermittent erythema and warmth • Flushing in patients with rosacea is usually limited to the face • Consider other common etiologies (e.g. menopause, anxiety disorder) or a tumor-related phenomenon (carcinoid syndrome, occult pheochromocytoma, mastocytosis) when additional anatomic sites are involved or there are associated symptoms such as tachycardia and sweating
Papules and pustules (previously termed papulopustular)	
Acne (vulgaris)	• Onset at a younger age • Comedones, both open and closed, and cysts • Greater involvement of the upper trunk
Periorificial dermatitis and steroid-induced rosacea	• See text
Demodicosis	• Spectrum includes *Demodex* folliculitis (see Ch. 38) and pityriasis folliculorum (see text) • Patients may be immunosuppressed (HIV infection, leukemia) • Involves face, especially the nose, and upper chest • Responds to topical ivermectin or permethrin ± oral ivermectin or metronidazole (see Table 38.1)
Tinea incognito, candidiasis	• Both can mimic rosacea, especially if topical corticosteroids have been used • KOH examination demonstrates hyphae or budding yeasts
Acneiform (papulopustular) eruptions due to EGFR inhibitors and other targeted therapies (e.g. MEK inhibitors, HER2 inhibitors)	• Occurs in up to 90% of patients on these drugs (see Fig. 37.15) • Abrupt onset • May also involve scalp, neck, and trunk
Follicular mucinosis	• Multiple papules but not pustules • Erythematous plaques and alopecia
Ocular rosacea	
Seborrheic dermatitis	• Involvement beyond the eyelid margin; may be accentuated in the eyelid creases
Drug-induced ocular rosacea	• Eyedrops used to treat other ocular disorders, e.g. glaucoma
Phymatous rosacea	
Lupus pernio (sarcoidosis)	• Violaceous indurated plaque of the distal nose
Discoid lupus erythematosus	• Erythema, scaling, follicular plugging, and tendency for scarring
Lupus vulgaris (cutaneous TB)	• See Table 75.7
Neoplasms	• Basal cell carcinoma, lymphoma, angiosarcoma, cutaneous metastases ("clown nose")

Table 37.4 Differential diagnosis of rosacea. Occasionally, trichostasis spinulosa has associated erythema, but detection of multiple hairs within the follicular orifice by dermoscopy or microscopic examination of follicular contents establishes the diagnosis. EGFR, epidermal growth factor receptor; HER2, human epidermal growth factor receptor 2; MEK, mitogen-activated protein kinase kinase; SLE, systemic lupus erythematosus; TB, tuberculosis.

Use of nonselective β-blockers (e.g. propranolol, carvedilol) to treat rosacea-associated flushing can be beneficial in selected individuals. Laser therapy (e.g. pulsed dye, potassium titanyl phosphate) and intense pulsed light can be used to ameliorate telangiectasias and improve erythema (see Ch. 137).

Papules and Pustules

In general, patients with inflammatory papules and pustules are treated with topical and/or systemic antibiotics (see Table 37.6)[43]. Although many of the antibiotics used to treat these lesions are the same as those used for acne vulgaris, the treatment course for rosacea is usually shorter (4–8 weeks as opposed to 3–4 months) and subantimicrobial doses may be effective. Sometimes successful treatment of the papulopustules may unmask background telangiectasias which then need to be addressed. Following successful clearance of inflammatory lesions, maintenance therapy (usually topical) should be instituted to avoid a likely relapse. Many patients with moderate and severe (grades 2 and 3) disease require repeated courses of systemic antibiotic therapy, but subsequent courses can often be shorter in duration, i.e. 3 to 4 weeks.

Topical ivermectin, which has both anti-inflammatory and antiparasitic properties, has become an important first-line therapy, as are

Downloaded for Anonymous User (n/a) at Egyptian Knowledge Bank from ClinicalKey.com by Elsevier on March 10, 2024. For personal use only. No other uses without permission. Copyright ©2024. Elsevier Inc. All rights reserved.

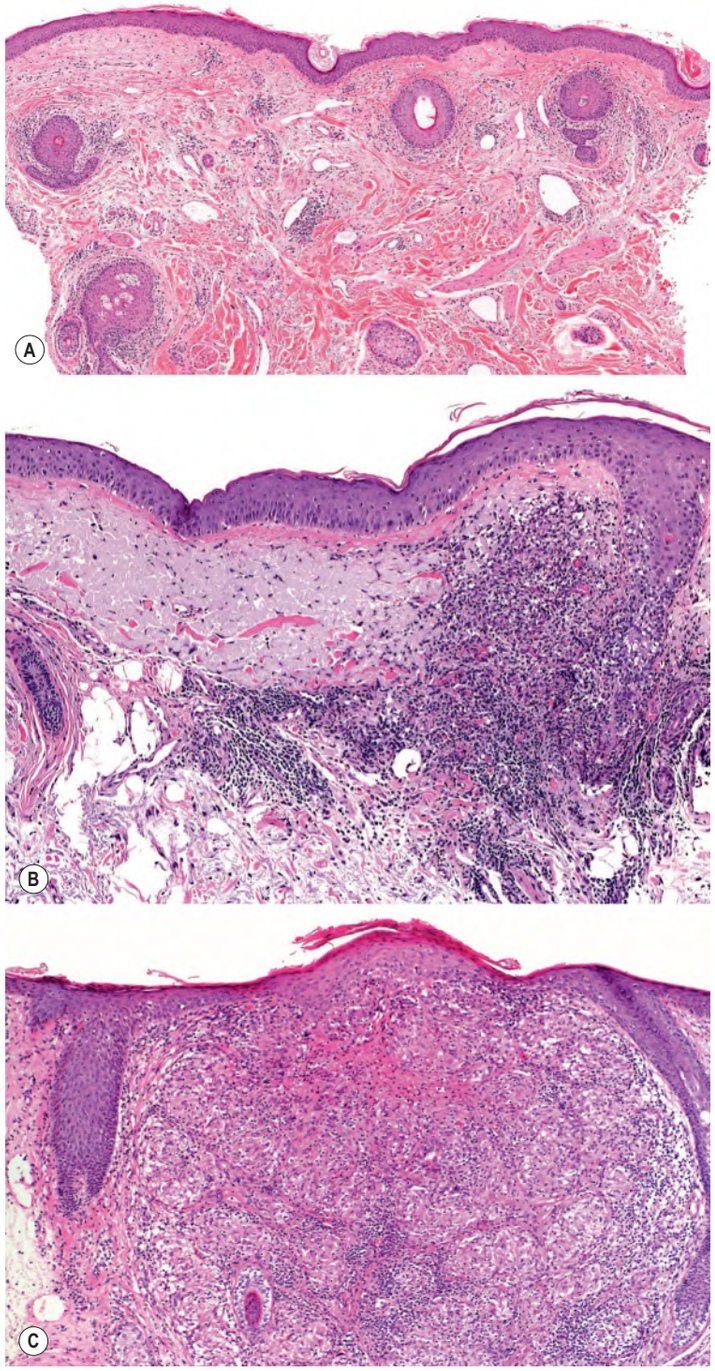

Fig. 37.11 Rosacea – range of histopathologic features. A *Erythema and telangiectasia* subtype with multiple dilated blood vessels as well as minimal perifollicular and perivascular lymphocytic infiltrates. **B** *Papules and pustules* subtype with a dense dermal infiltrate of lymphocytes, predominantly surrounding an involved hair follicle. There is also marked solar elastosis. **C** *Granulomatous variant* of rosacea with a nodular granulomatous infiltrate composed of histiocytes, histiocytic giant cells, and admixed lymphocytes filling the upper interfollicular dermis. *Courtesy Lorenzo Cerroni, MD.*

topical metronidazole and azelaic acid[44]. Other topical agents include sodium sulfacetamide +/− sulfur, minocycline[45], clindamycin, benzoyl peroxide[46], retinoids, and permethrin. Low-dose isotretinoin[47] and photodynamic therapy[48] are treatment options in patients whose lesions prove resistant to first-line therapies.

Other Forms of Rosacea

Rhinophyma is the type of phymatous rosacea most amenable to treatment (see Table 37.6). Mild disease may be responsive to low-dose isotretinoin, although conclusive evidence of efficacy is lacking. More severe (grades 2 and 3) disease responds best to physical modalities such as CO_2 laser therapy, electrosurgery, or surgical excision (see Fig. 140.7). Longitudinal evaluation of patients treated with CO_2 laser therapy suggests that improvement persists long-term[49]. Other sites of phymatous rosacea are very rare and there are no established therapeutic interventions.

Ocular rosacea is a common entity that is frequently underdiagnosed[50]. Patients with mild ocular rosacea (grade 1 disease) often respond to washing of the eyelid margins with gauze soaked with dilute, tear-free baby shampoo. This is combined with an oily tear replacement. Burning or stinging with crusting of the eyelid margins or the formation of a chalazion or hordeolum are manifestations of moderate (grade 2) disease and treatment consists of topical and/or systemic antibiotics (see Table 37.6). Pain, photophobia, and visual disturbances are features of severe (grade 3) disease. Such symptoms require prompt referral to an ophthalmologist.

Granulomatous rosacea is difficult to treat, and no consensus exists regarding first-line therapies. Anecdotally, options include dapsone, minocycline, isotretinoin, hydroxychloroquine, and the 1450-nm diode laser. Anecdotally, apremilast has been reported to improve LMDF.

While some authors consider *rosacea fulminans* (pyoderma faciale; Fig. 37.12) and *rosacea conglobata* to be within the rosacea spectrum, others view them as variants of acne vulgaris. Nonetheless, systemic corticosteroids are required to control the aggressive inflammation observed in both disorders, followed by the use of oral isotretinoin. Scarring can be a sequela despite these interventions.

GENERAL RECOMMENDATIONS FOR FACIAL SKIN CARE AND EDUCATION IN PATIENTS WITH ROSACEA
Facial skin care
• Wash with lukewarm water and use soap-free cleansers or synthetic detergents (syndets) that are pH balanced • Cleansers are applied gently with fingertips • Use sunscreens with both UVA and UVB protection and an SPF ≥30 • Sunscreens containing the inorganic filters titanium dioxide and/or zinc oxide are usually well tolerated • Use cosmetics and sunscreens that contain protective silicones • Water-soluble facial powder containing inert green pigment helps to neutralize the perception of erythema • Moisturizers containing humectants (e.g. glycerin) and occlusives (e.g. petrolatum) help to repair the epidermal barrier • Avoid astringents, toners, and abrasive exfoliators • Avoid cosmetics that contain alcohol, menthols, camphor, witch hazel, fragrance, peppermint, and eucalyptus oil • Avoid waterproof cosmetics and heavy foundations that are difficult to remove without irritating solvents or physical scrubbing • Avoid procedures such as glycolic peels or dermabrasion
Patient education
• Reassure the patient about the benign nature of the disorder and the rarity of rhinophyma, particularly in women • Emphasize the chronicity of the disease and the likelihood of exacerbations • Direct patients to information websites such as those of the National Rosacea Society (www.rosacea.org) or the American Academy of Dermatology (www.aad.org) • Advise avoidance of recognized triggers • Explain the importance of compliance with topical regimens • Educate on the importance of sun avoidance

Table 37.5 General recommendations for facial skin care and education in patients with rosacea.

ROSACEA-LIKE DISORDERS

- *Periorificial dermatitis*, originally termed perioral dermatitis, bears a superficial resemblance to rosacea, but the distribution pattern (perioral, perinasal, and/or periocular rather than centrofacial) and lesional morphology differ. In periorificial dermatitis, there are monomorphous superficial pinpoint pustules and/or pink papules as well as patches and thin plaques, some of which have fine scale (Fig. 37.13). A history of topical or inhaled corticosteroid use may be elicited. Overuse of cosmetics and moisturizers has also been

Downloaded for Anonymous User (n/a) at Egyptian Knowledge Bank from ClinicalKey.com by Elsevier on March 10, 2024. For personal use only. No other uses without permission. Copyright ©2024. Elsevier Inc. All rights reserved.

MEDICAL AND SURGICAL THERAPIES FOR ROSACEA	
Treatment	**Comments and/or doses**
Erythema and telangiectasia (previously termed erythematotelangiectatic)	
Facial skin care recommendations (see Table 37.5)	Particularly useful as this subtype is prone to skin irritation and "sensitivity"
Photoprotection	UVR may potentiate dermal matrix damage
Topical agents, e.g. azelaic acid, metronidazole	May reduce erythema, but their use is often limited by their irritant effects
Topical brimonidine tartrate (0.33% gel)*,†	Selective α_2-adrenergic agonist that improves erythema; effects are temporary and possible rebound erythema
Topical oxymetazoline HCl (1% cream)*	Selective α_{1A}-adrenergic agonist and partial α_2-adrenergic agonist that improves erythema; temporary effects are temporary and possible rebound
Laser therapy†	Use of vascular lasers (e.g. pulsed dye, potassium titanyl phosphate) as well as intense pulsed light may improve grades 2 and 3 (see Ch. 137)
Papules and pustules (previously termed papulopustular)	
Topical	
Ivermectin (1% cream)*,† once daily	More effective than placebo and slightly more effective than topical metronidazole in randomized controlled trials
Metronidazole (0.75% gel, cream, or lotion; 1% gel or cream)*,† once or twice daily	Can be used as initial treatment to clear inflammatory lesions or as indefinite maintenance therapy
Azelaic acid (15% gel and foam)*,† twice daily	Appears to be more effective than topical metronidazole but with more side effects, e.g. irritation Azelaic acid (20% cream twice daily) is a non-FDA-approved alternative dose
Sodium sulfacetamide (10%) ± sulfur (5%) lotion* or both in a cream*, gel*, foam*, or cleanser (wash, pads)* once or twice daily	Gel and cleanser formulations may include 10% urea
Minocycline (1.5% foam)* once daily	More effective than vehicle foam in reduction of inflammatory lesion count at 12 weeks[45]; well tolerated
Erythromycin (2% gel and solution) twice daily	Alcohol in gel and solution may reduce tolerance
Clindamycin (1% lotion) once daily	
Benzoyl peroxide 5% cream	Microencapsulated formulations* may be better tolerated[46]
Benzoyl peroxide 2.5%–5% plus clindamycin 1%–1.2% daily	May cause skin irritation
Tretinoin (0.025% cream; 0.05% cream; 0.01% gel) daily	Alters epidermal keratinization and may improve photodamage Poorly tolerated by some patients
Permethrin (5% cream) daily–weekly	As effective as topical metronidazole for the treatment of papules and erythema
Pimecrolimus (1% cream) or tacrolimus (0.03%, 0.1% ointment) twice daily	Some studies have shown improvement in erythema, but there have been reports of exacerbations and induction of rosaceiform dermatitis
Systemic	
Doxycycline (low-dose)	40 mg daily (30 mg immediate release and 10 mg delayed release)*,† for 4–8 weeks; as effective as the 100 mg dose but with fewer adverse effects 20 mg twice daily for 4–8 weeks may be more cost-effective
Doxycycline	50–100 mg once or twice daily for 4–8 weeks
Minocycline	50–100 mg twice daily or sustained action formula (1 mg/kg) daily for 4–8 weeks‡
Tetracycline†	250–500 mg twice daily for 4–8 weeks
Erythromycin	250–500 mg once or twice daily for 4–8 weeks
Azithromycin	250–500 mg (5–10 mg/kg) thrice weekly for 4–8 weeks
Metronidazole	200 mg once or twice daily for 4–8 weeks
Isotretinoin†	10–20 mg daily for 4–6 months
Phymatous	
Isotretinoin	May reduce nasal volume and halt the progression of rhinophyma
Electrosurgery	Can effectively debulk and resculpt the nose
CO_2 laser	
Surgical excision	
Ocular	
Eyelid hygiene and artificial tears	Frequently used to treat mild disease
Topical antibiotics (metronidazole 0.75% gel, erythromycin 0.5% ophthalmic ointment, azithromycin 1% ophthalmic solution)	Useful for maintaining remission following treatment of grades 2 and 3 disease with systemic antibiotics
Cyclosporine 0.5% ophthalmic emulsion†	More effective than artificial tears
Systemic antibiotics (see above section)	For grade 2–3 disease

*FDA-approved treatments for rosacea (evidence-based support = 1).
†In a Cochrane review of randomized controlled trials conducted for moderate to severe rosacea, these were the treatments shown to be effective[38].
‡In a 16-week trial, minocycline 100 mg daily was non-inferior to doxycycline 40 mg daily[54].

Table 37.6 Medical and surgical therapies for rosacea. If moderate to severe flushing persists despite avoidance of triggers, beta-blockers (e.g. carvedilol, nadolol) can be tried (see Ch. 106). Ophthalmic corticosteroids (e.g. dexamethasone, fluocinolone) can be used short-term to treat severe eyelid inflammation. UVR, ultraviolet radiation.

Downloaded for Anonymous User (n/a) at Egyptian Knowledge Bank from ClinicalKey.com by Elsevier on March 10, 2024. For personal use only. No other uses without permission. Copyright ©2024. Elsevier Inc. All rights reserved.

implicated in exacerbating periorificial dermatitis, and intolerance of sunlight and hot water are common symptoms.

A 4- to 8-week course of oral antibiotics (e.g. doxycycline, erythromycin, tetracycline, minocycline, often at subantimicrobial doses) is usually effective in clearing the skin; azithromycin 500 mg three times weekly for 4–8 weeks represents an alternative therapy (see Table 37.6). If topical corticosteroids are implicated in causing perioral dermatitis, they should be discontinued. However, a reduction in the strength and frequency of application of the topical corticosteroid, as opposed to an abrupt discontinuation, may help to avoid a significant rebound flare of the disease. Clearance is usually not followed by a subsequent relapse unless the patient is re-exposed to the inciting trigger. A variant seen in children is referred to as chronic granulomatous periorificial disease of children.

Fig. 37.12 Rosacea fulminans (pyoderma faciale). Sudden onset of tender plaques on the chin studded with pustules. The patient was pregnant and had no history of rosacea or acne vulgaris.

- *Steroid-induced "rosacea"* is a facial eruption in which erythema, papules, and pustules, and in some patients atrophic changes such as telangiectasias, develop from the repeated application of moderate to high potency topical corticosteroids (Fig. 37.14). As with periorificial dermatitis, reducing the strength of the topical corticosteroid as well as the frequency of application (rather than an abrupt discontinuation) is advisable to reduce a rebound flare. Systemic doxycycline, tetracycline, minocycline, azithromycin or erythromycin may also be required for 4 to 8 weeks. Although they have been reported to induce rosaceiform dermatitis, topical calcineurin inhibitors can also be used to reduce inflammation.
- *Rosaceiform dermatitis* is a term usually employed to describe a cutaneous reaction to a drug that clinically resembles rosacea. It is due primarily to topical or systemic corticosteroids and topical calcineurin inhibitors[51], and it is characterized by facial erythema plus small papules and numerous pustules. The distribution on the face is usually widespread, although there are exceptions. Abundant *Demodex* mites have been found on the facial skin of some of these patients, possibly the result of the immunomodulating effects of the inciting medications. This term is also used by some clinicians to describe patients with features of both rosacea and facial dermatitis.
- *Acneiform papulopustular eruption due to epidermal growth factor receptor (EGFR) inhibitors and other targeted therapies* – see Table 37.4 and Fig. 37.15.
- *Idiopathic facial aseptic granuloma* (IFAG) usually presents with a single erythematous nodule on the cheek of a child which persists for several months then spontaneously resolves. One theory is that it represents a form of childhood granulomatous rosacea.

Fig. 37.13 Periorificial dermatitis (often referred to as perioral dermatitis). A–C Pink papules, patches, and thin plaques as well as pinpoint superficial pustules around orifices, i.e. in a perioral, perinasal, and/or periorbital distribution pattern. In contrast to papulopustular rosacea, the papules are classically at the same stage of evolution. **D** Close-up of the characteristic pinpoint pustules (arrows). **E** Granulomatous periorificial disease in a child with monomorphous pink papules that have become confluent around the mouth. The eruption, which had previously worsened upon treatment with topical and oral corticosteroids, resolved with a 6-week course of azithromycin. *A, Courtesy Frank C. Powell, MD; B–D, Courtesy Kalman Watsky, MD; E, Courtesy Julie V. Schaffer, MD.*

Downloaded for Anonymous User (n/a) at Egyptian Knowledge Bank from ClinicalKey.com by Elsevier on March 10, 2024. For personal use only. No other uses without permission. Copyright ©2024. Elsevier Inc. All rights reserved.

Fig. 37.14 Steroid rosacea. A Milder disease in an adult with scattered erythematous papules and papulopustules of the central face. **B** Severe disease in a child with confluence of erythematous papulopustules. *A, Courtesy Kalman Watsky, MD.*

Fig. 37.15 Papulopustular eruption due to an epidermal growth factor receptor (EGFR) inhibitor. There is a resemblance to rosacea but the onset is more abrupt. *Courtesy Frank C. Powell, MD.*

Fig. 37.16 Morbihan disease. Erythematous, firm, non-pitting, asymptomatic swelling of the upper midface. Areas of greatest involvement can acquire a "peau d'orange" appearance. *Courtesy Frank C. Powell, MD.*

- *Demodicosis* encompasses *Demodex* folliculitis (see Ch. 38) and pityriasis folliculorum. The latter is a poorly recognized disorder that primarily affects women in the 20- to 40-year age group who rarely allow water to contact their face and who instead often apply moisturizing and cleansing creams as well as cosmetic preparations. There is a roughened, whitish scaling skin surface on a background of faint erythema, along with some scattered fine papules and pustules that are not limited to the central face. The patient usually complains of increased skin sensitivity. KOH examination of skin scrapings demonstrates multiple dead and some live *Demodex* mites. Nightly application of topical ivermectin for 4 to 6 weeks is usually effective when combined with a facial washing routine.
- *Morbihan disease* (solid facial edema) is a rare facial disorder characterized by a progressive and persistent, asymptomatic, firm non-pitting swelling of the central upper face that is associated with fixed facial erythema (Fig. 37.16). Lymphedema in this location can result from a number of initiating factors, from injuries to contact allergy[52] to acne vulgaris. While rosacea has also been associated with Morbihan disease[53], there are patients with no history of a facial dermatosis. Histologically, it may be indistinguishable from other forms of rosacea, including presenting with granulomatous features. Lymphedema can also be seen. There is no consistently effective therapy, but prolonged courses of antihistamines and low-dose oral isotretinoin have been reported as helpful in individual patients.
- Patients with *Haber syndrome*, currently viewed as a subtype of Dowling–Degos disease with comedones of the trunk and pitted scars, can also have early-onset, rosacea-like facial erythema.

Acknowledgment

The editors wish to thank Dr. Frank C. Powell for his valuable contributions to this chapter in the previous editions.

Additional figures available in our eBook (see inside front cover for access code).

Downloaded for Anonymous User (n/a) at Egyptian Knowledge Bank from ClinicalKey.com by Elsevier on March 10, 2024. For personal use only. No other uses without permission. Copyright ©2024. Elsevier Inc. All rights reserved.

REFERENCES

1. Tan J, Almeida LM, Bewley A, et al. Updating the diagnosis, classification and assessment of rosacea: recommendations from the global ROSacea COnsensus (ROSCO) panel. *Br J Dermatol*. 2017;176:431–438.
2. Gallo RL, Granstein RD, Kang S, et al. Standard classification and pathophysiology of rosacea: the 2017 update by the National Rosacea Society Expert Committee. *JAAD*. 2018;78:148–155.
3. Gether L, Overgaard LK, Egeberg A, Thyssen JP. Incidence and prevalence of rosacea: a systematic review and meta-analysis. *Br J Dermatol*. 2018;179:282–289.
4. Tan J, Schöfer H, Araviiskaia E, et al.; RISE study group. Prevalence of rosacea in the general population of Germany and Russia – The RISE study. *J Eur Acad Dermatol Venereol*. 2016;30:428–434.
5. Powell FC. Rosacea. *N Eng J Med*. 2005;352:793–803.
6. Alexis AF, Callender VD, Baldwin HE, et al. Global epidemiology and clinical spectrum of rosacea, highlighting skin of color: review and clinical practice experience. *J Am Acad Dermatol*. 2019;80:1722–1729.
7. Holmes AD, Spoendlin J, Chien AL, et al. Evidence-based update on rosacea comorbidities and their common physiologic pathways. *J Am Acad Dermatol*. 2018;78:156–166.
8. Chang ALS, Raber I, Xu J, et al. Assessment of the genetic basis of rosacea by genome-wide association study. *J Invest Dermatol*. 2015;135:1548–1555.
9. Yamasaki K, Di Nardo A, Barden A, et al. Increased serine protease activity and cathelicidin promotes skin inflammation in rosacea. *Nat Med*. 2007;13:975–980.
10. Yoon SH, Hwang I, Lee E, et al. Antimicrobial peptide LL-37 drives rosacea-like skin inflammation in an NLRP3-dependent manner. *J Invest Dermatol*. 2021;141:2885–2894.
11. Yamasaki K, Kanada K, Macleod DT, et al. TLR2 expression is increased in rosacea and stimulates enhanced serine protease production by keratinocytes. *J Invest Dermatol*. 2011;131:688–697.
12. Määttä M, Kari O, Tervahartiala T, et al. Tear fluid levels of MMP-8 are elevated in ocular rosacea: treatment effect of oral doxycycline. *Graefes Arch Clin Exp Ophthalmol*. 2006;244:957–962.
13. Margalit A, Kowalczyk MJ, Żaba R, Kavanagh K. The role of altered cutaneous immune responses in the induction and persistence of rosacea. *J Dermatol Sci*. 2016;82:3–8.
14. Buhl T, Sulk M, Nowak P, et al. Molecular and morphological characterization of inflammatory infiltrate in rosacea reveals activation of Th1/Th17 pathways. *J Invest Dermatol*. 2015;135:2198–2208.
15. Lonne-Rahm SB, Fischer T, Berg M. Stinging and rosacea. *Acta Derm Venereol (Stockh)*. 1999;79:460–461.
16. Steinhoff M, Buddenkotte J, Aubert J, et al. Clinical, cellular, and molecular aspects in the pathophysiology of rosacea. *J Invest Dermatol Symp Proc*. 2011;15:2–11.
17. Guzman-Sanchez DA, Ishiuji Y, Patel T, et al. Enhanced blood flow and sensitivity to noxious heat stimuli in papulopustular rosacea. *J Am Acad Dermatol*. 2007;57:800–805.
18. Gomaa AH, Yaar M, Eyada MM, Bhawan J. Lymphangiogenesis and angiogenesis in non-phymatous rosacea. *J Cutan Pathol*. 2007;34:748–753.
19. Ballaun C, Weninger W, Uthman A, et al. Human keratinocytes express the three major splice forms of vascular endothelial growth factor. *J Invest Dermatol*. 1995;104:7–10.
20. Wlaschek M, Briviba K, Stricklin GP, et al. Singlet oxygen may mediate the ultraviolet A-induced synthesis of interstitial collagenase. *J Invest Dermatol*. 1995;104:194–198.
21. Helfrich YR, Maier LE, Cui Y, et al. Clinical, histologic, and molecular analysis of differences between erythematotelangiectatic rosacea and telangiectatic photoaging. *JAMA Dermatol*. 2015;151:825–836.
22. Dirshka T, Tronnier H, Folster-Holst R. Epithelial barrier function and atopic diathesis in rosacea and perioral dermatitis. *Br J Dermatol*. 2004;150:1136–1141.
23. Dahl MV. Pathogenesis of rosacea. *Adv Dermatol*. 2001;17:29–45.
24. Ní Raghallaigh S, Bender K, Lacey N, et al. The fatty acid profile of the skin surface lipid layer in papulopustular rosacea. *Br J Dermatol*. 2012;166:279–287.
25. Ní Raghallaigh S, Powell FC. Epidermal hydration levels in patients with rosacea improve after minocycline therapy. *Br J Dermatol*. 2014;117:259–266.
26. Bonnar E, Eustace P, Powell FC. The Demodex mite population in rosacea. *J Am Acad Dermatol*. 1993;28:443–448.
27. Forton F, Seys B. Density of Demodex folliculorum in rosacea: a case-control study using a standardised skin surface biopsy. *Br J Dermatol*. 1993;128:650–659.
28. Georgala S, Katoulis AC, Kylafis GD, et al. Increased density of Demodex folliculorum and evidence of delayed hypersensitivity reaction in subjects with papulopustular rosacea. *J Eur Acad Dermatol Venereol*. 2001;15:441–444.
29. Lacey N, Delaney S, Kavanagh K, Powell FC. Mite-related bacterial antigens stimulate inflammatory cells in rosacea. *Br J Dermatol*. 2007;157:474–481.
30. Lacey N, Ní Raghallaigh S, Powell FC. Demodex mites – commensals, parasites or mutualistic organisms? *Dermatology*. 2011;222:128–130.
31. Jørgensen AR, Egeberg A, Gideonsson R, et al. Rosacea is associated with Helicobacter pylori: a systematic review and meta-analysis. *J Eur Acad Dermatol Venereol*. 2017;31:2010–2015.
32. Wilkin J, Dahl M, Detmar M, et al. Standard classification of rosacea: Report of the National Rosacea Society Expert Committee on the Classification and Staging of Rosacea. *J Am Acad Dermatol*. 2002;46:584–587.
33. Roberts JO, Ward CM. Rhinophyma. *J R Soc Med*. 1985;78:678–681.
34. Michaels JD, Cook-Norris RH, Lehman JS, Gibson LE. Adult with papular eruption on the central aspect of the face. *J Am Acad Dermatol*. 2014;71:410–412.
35. Jansen T, Plewig G, Kligman AM. Diagnosis and treatment of rosacea fulminans. *Dermatology*. 1994;188:251–254.
36. Del Rosso JQ. Adjunctive skin care in the management of rosacea: cleansers, moisturizers and photoprotectants. *Cutis*. 2005;75:17–21.
37. Del Rosso JQ, Baum EW. Comprehensive medical management of rosacea: an interim study report and literature review. *J Clin Aesthet Dermatol*. 2008;1:20–25.
38. van Zuuren EJ, Fedorowicz Z. Interventions for rosacea: abridged updated Cochrane systematic review including GRADE assessments. *Br J Dermatol*. 2015;173:651–662.
39. van der Linden MMD, van Ratingen AR, van Rappard DC, et al. DOMINO, doxycycline 40 mg vs. minocycline 100 mg in the treatment of rosacea: a randomized, single-blinded, noninferiority trial, comparing efficacy and safety. *Br J Dermatol*. 2017;176:1465–1474.
40. Wilkin J, Dahl M, Detmar M, et al. Standard grading system for rosacea: Report of the National Rosacea Society Expert Committee on the Classification and Staging of Rosacea. *J Am Acad Dermatol*. 2004;50:907–912.
41. Fowler J, Jackson M, Moore A. Efficacy and safety of once-daily topical brimonidine tartrate gel 0.5% for the treatment of moderate to severe facial erythema of rosacea: results of two randomized, double-blind, vehicle-controlled pivotal studies. *J Drugs Dermatol*. 2013;12:650–656.
42. Oxymetazoline cream (Rhofade) for rosacea. *Med Lett Drugs*. Ther. 2017;59:84–88.
43. Pelle MT, Crawford GH, James WD. Rosacea: II. Therapy. *J Am Acad Dermatol*. 2004;51:499–512.
44. Taieb A, Ortonne JP, Ruzicka T, et al. Superiority of ivermectin 1% cream over metronidazole 0.75% cream in treating inflammatory lesions of rosacea: a randomized, investigator-blinded trial. *Br J Dermatol*. 2015;172:1103–1110.
45. Gold LS, Del Rosso JQ, Kircik L, et al. Minocycline 1.5% foam for the topical treatment of moderate to severe papulopustular rosacea: results of 2 phase 3, randomized, clinical trials. *J Am Acad Dermatol*. 2020;82(5):1166–1173.
46. Leyden JJ. Randomized, phase 2, dose-ranging study in the treatment of rosacea with encapsulated benzoyl peroxide gel. *J Drugs Dermatol*. 2014;13:685–688.
47. Hyunhee P, Del Rosso DO. Use of oral isotretinoin in the management of rosacea. *J Clin Aesthet Dermatol*. 2011;4:54–61.
48. Bryld LE, Jemec GBE. Photodynamic therapy in a series of rosacea patients. *J Eur Acad Dermatol Venereol*. 2007;21:1199–1202.
49. Madan V, Ferguson JE, August P. Carbon dioxide laser treatment of rhinophyma: a review of 124 patients. *Brit J Dermatol*. 2009;161:814–818.
50. Viera AC, Mannis MJ. Ocular rosacea: common and commonly missed. *J Am Acad Dermatol*. 2013;69:S36–S41.
51. Antille C, Saurat JH, Lubbe J. Induction of rosaceiform dermatitis during treatment of facial inflammatory dermatoses. *Arch Dermatol*. 2004;140:457–460.
52. Wohlrab J, Lueftl M, Marsch WC. Persistent erythema and edema of the midthird and upper aspect of the face (morbus morbihan): evidence of hidden immunologic contact urticaria and impaired lymphatic drainage. *J Am Acad Dermatol*. 2005;52:595–602.
53. Plewig G, Kligman AM. *Acne and Rosacea*. 2nd ed. Berlin: Springer-Verlag; 1993.
54. van der Linden MMD, van Ratingen AR, van Rappard DC, et al. Doxycycline 40 mg vs. minocycline 100 mg in the treatment of rosacea: a randomized, single-blinded, noninferiority trial, comparing efficacy and safety. *Br J Dermatol*. 2017;176:1465–1474.

Downloaded for Anonymous User (n/a) at Egyptian Knowledge Bank from ClinicalKey.com by Elsevier on March 10, 2024. For personal use only. No other uses without permission. Copyright ©2024. Elsevier Inc. All rights reserved.

eFig. 37.1 Moderate to severe papulopustular rosacea. There is a typical centrofacial distribution of erythema, telangiectasias, papules, and pustules. In addition, the skin has a scaly, crusty surface and this is often a sign of more severe disease. *Courtesy Frank C. Powell, MD.*

eFig. 37.2 Rosacea fulminans (pyoderma faciale). Striking plaque on the cheek studded with pustules.

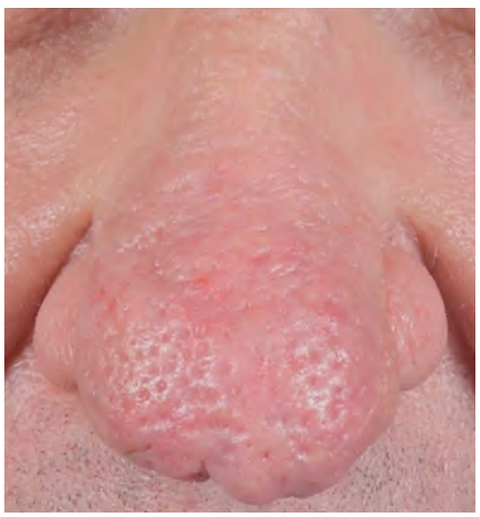

eFig. 37.3 Earlier stage of rhinophyma with prominent follicular openings (patulous follicles) and evidence of the early nodular swelling. *Courtesy Frank C. Powell, MD.*

eFig. 37.4 Rhinophyma with distortion of nasal tissue due to nodular hypertrophy of sebaceous glands. Electrosurgery or laser therapy can be used to debulk and resculpt this nose. *Courtesy Frank C. Powell, MD.*

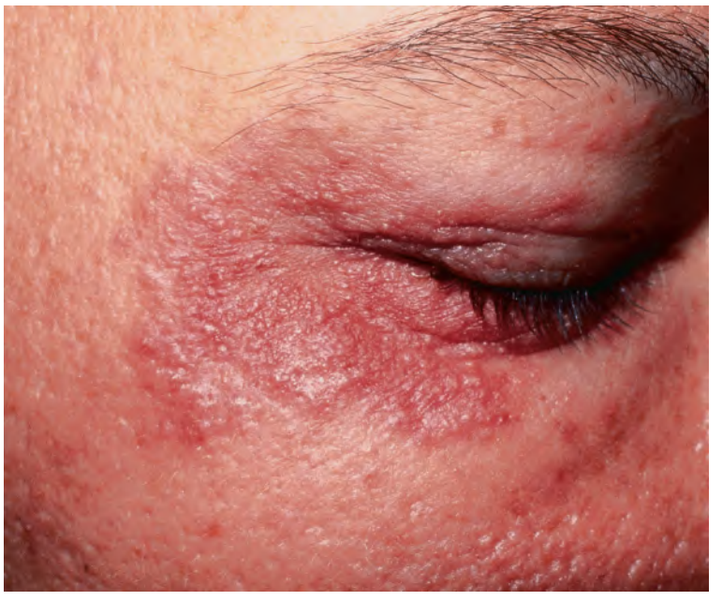

eFig. 37.5 Periocular dermatitis with multiple fine papules and pustules superimposed on a pink plaque. *Courtesy Ronald P. Rapini, MD.*

eFig. 37.6 Periocular (periorificial) dermatitis in a 17-year-old male patient. Note the clustered pinpoint pustules within an erythematous plaque. *Courtesy Kalman Watsky, MD.*

Downloaded for Anonymous User (n/a) at Egyptian Knowledge Bank from ClinicalKey.com by Elsevier on March 10, 2024. For personal use only. No other uses without permission. Copyright ©2024. Elsevier Inc. All rights reserved.

eFig. 37.7 Periocular (periorificial) dermatitis involving the forehead and eyelid. *Courtesy Kalman Watsky, MD.*

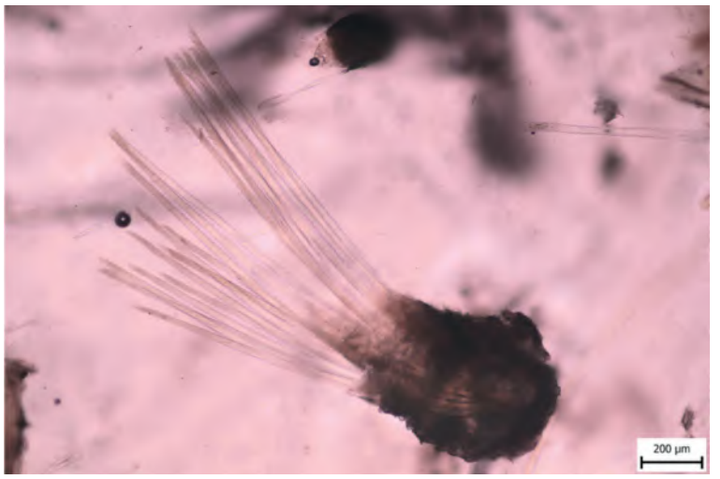

eFig. 37.10 Trichostasis spinulosa – microscopic examination of follicular contents. Tuft of multiple vellus hairs. *Courtesy Frank C. Powell, MD.*

eFig. 37.8 Severe steroid rosacea. The patient had been applying clobetasol, a class I corticosteroid, to the face. *Courtesy Kalman Watsky, MD.*

eFig. 37.9 Trichostasis spinulosa presenting with nasal erythema and prominence of the follicular orifices. *Courtesy Frank C. Powell, MD.*

Downloaded for Anonymous User (n/a) at Egyptian Knowledge Bank from ClinicalKey.com by Elsevier on March 10, 2024. For personal use only. No other uses without permission. Copyright ©2024. Elsevier Inc. All rights reserved.